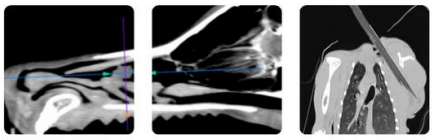

Teleradiology
Educational Teleconsultation Services™

PATIENT

Florence Lanier

SPECIES

Feline

BREED

DLH

SEX

FS

AGE

7yr

INTERPRETED BY

Nele Eley (Ondreka), DVM Dr. med. vet., DipECVDI

HOSPITAL NAME

Gentle Doctor Animal Hospital

REFERRING VET

Dr A Taplett

INVOICE

24513

DATE

04/15/2026

PRESENTING CLINICAL SIGNS

Malignant dermal melanoma removed between her shoulder blades this month. Working on staging Abnormal PE/Chem/CBC/UA Results: Concern for possible nodule on left lateral over the heart margin

RADIOGRAPHIC STUDY OF THE THORAX

Right/left lateral and ventrodorsal views totaling 4 images are available for review.

RADIOGRAPHIC FINDINGS

Lung fields are overall within normal limits. No convincing evidence of multiple pulmonary nodules, alveoli and /or interstitial pattern are seen. There is no evidence of pleural effusion.

On the right lateral projection there is a questionable ~ 5 mm size soft tissue opacity superimposed over the cardiac silhouettes, see the image below. This opacity is not identified on the left lateral or orthogonal views and not consistently reproducible. The appearance is most consistent with formation artifact. A small pulmonary nodule is considered less likely.

The patient's body condition score is elevated.

Cardiac size is subjectively within normal limits. Vertebral heart score is ~ 7.9.

No mediastinal mass effect is seen.

Course and position of the trachea are within normal limits.

RADIOGRAPHIC DIAGNOSIS

- No definitive radiographic evidence of thoracic metastatic disease at this time
- Questionable 5 mm size opacity on single projection: right lateral view, most likely formation artifact, early pulmonary metastasis cannot be completely excluded

INTERPRETATION OF FINDINGS & FURTHER RECOMMENDATIONS

The radiographic study of the thorax reveals no definitive radiographic evidence of thoracic metastatic disease. No definitive pulmonary nodules are identified. The questioned opacity is not reproducible, significantly lowering suspicion for true metastatic disease.

Thoracic CT should be considered for definitive metastatic staging as it offers greater sensitivity compared with radiographs and for clarification of the questionable opacity. Alternatively thoracic recheck radiographs can be obtained in 6-8 weeks for interval monitoring.

SonoPath
FOSTERING THE ART OF VETERINARY MEDICINE™

SonoPath.com info@sonopath.com 1.800.838.4268

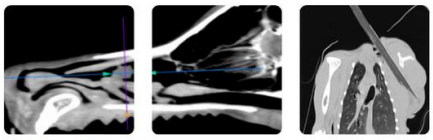

Teleradiology
Educational Teleconsultation Services™

PATIENT

Florence Lanier

SPECIES

Feline

BREED

DLH

SEX

FS

AGE

7yr

INTERPRETED BY

Nele Eley (Ondreka), DVM Dr. med. vet., DipECVDI

HOSPITAL NAME

Gentle Doctor Animal Hospital

REFERRING VET

Dr A Taplett

INVOICE

24513

DATE

04/15/2026

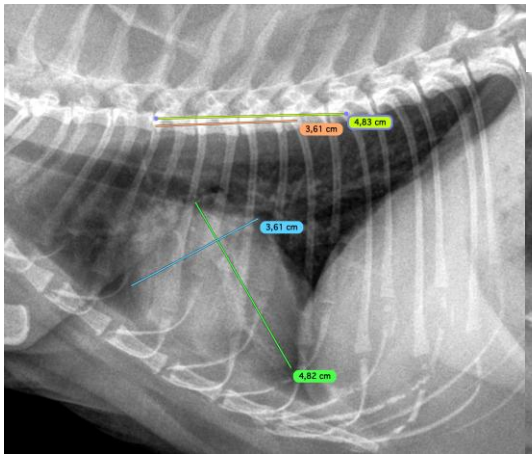

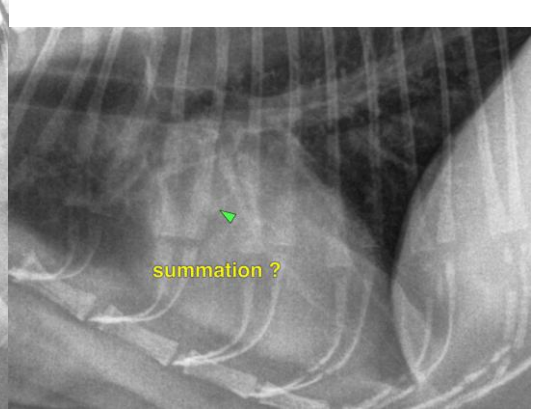

The information and recommendations provided are based on the images presented by the referring veterinarian. No evaluation can be communicated regarding pathology that was not visible in the image/video clips provided.

Thank you for this referral. If the clinical or image interpretation does not parallel your findings or if I can be of any further assistance please contact me.

Nele Eley (Ondreka), DVM, Dr. med. vet., DipECVDI
European Specialist in Veterinary Diagnostic Imaging, Cert. Radiology,
Senior lecturer University of Giessen/Germany, Veterinary Faculty, Department of Radiology.
info@sonopath.com